



Pediatric and Adolescent Sports Medicine Update

3rd Quarter 2014

Hip Dysplasia in the Young Athlete

by Drew W. Warnick, M.D.

Hip pain in adolescents and young active adults may be an early sign of hip dysplasia. This is a condition in which one or more areas of the hip joint have not developed normally.

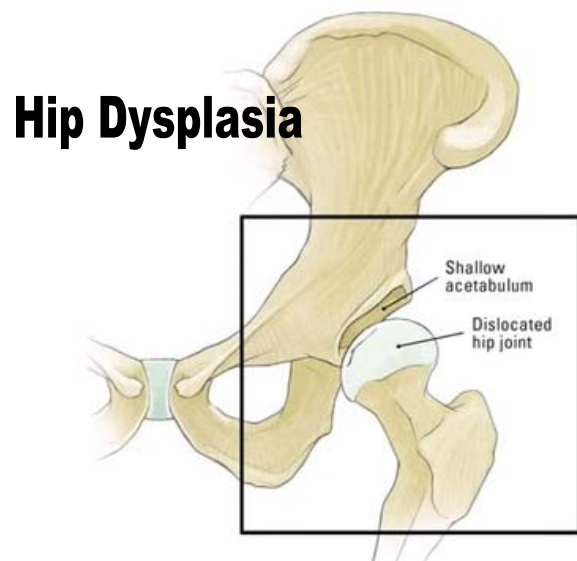
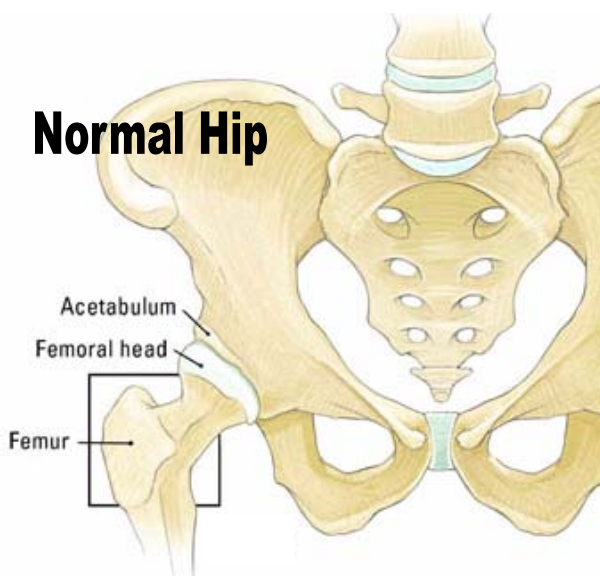
In individuals with hip dysplasia, the acetabulum or socket does not develop fully, making it too shallow to adequately contain and support the femoral head. When this abnormality is present, excessive stress and shear forces are present on the socket leading to premature degeneration and arthritis over a number of years.

Because participation in sports activity places a large amount of stress on the hip joint, adolescents and young adults with hip dysplasia whom participate in sports are more likely to present with symptoms earlier than those whom do not.

Diagnosis In addition to a thorough physical exam and patient history, hip dysplasia can be diagnosed with x-rays and magnetic resonance imaging. Highly sophisticated MRI techniques can show early degenerative changes in the joint and can show labral tears.

Causes The cause of abnormal development of the acetabulum is not yet well understood. Although there appears to be a relationship between the position of the fetus in the womb, breech births, and a family history of dysplasia. Screening for hip dysplasia is routine care for newborns in the United States, but it is impossible to detect all cases of eventual dysplasia in the newborn period. Some of these abnormalities are relatively mild and may not be detected early or cause symptoms until the individual reaches adolescence or later. Hip dysplasia is also more common in women than in men.

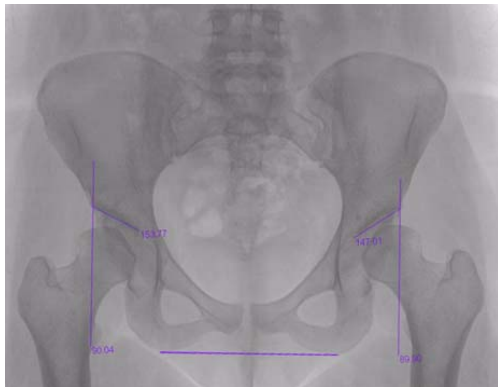
If you would like more information about treatment of hip dysplasia, please call and make an appointment with our hip preservation specialist Dr. Drew Warnick.



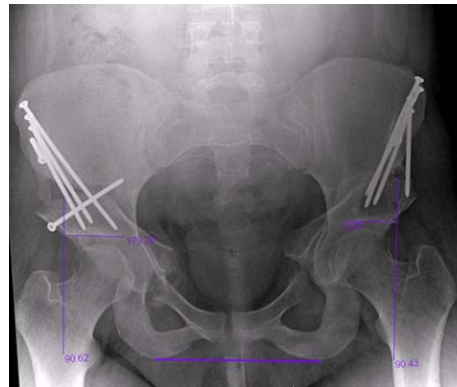

Treatment Treatment for hip dysplasia focuses on preserving the hip and avoiding early hip replacement. This is why it is important to be evaluated for hip pain promptly. Patients with hip dysplasia who experience pain and have limited damage to their cartilage may be candidates for periacetabular osteotomy (PAO). This procedure involves a series of cuts to the bone to reorient the acetabulum over the femoral head, in order to increase coverage, decrease hip stress and restore a more normal anatomy. Screws are then placed in the bones to stabilize this position. This procedure has been shown to have very good results even up to 20-25 years after the procedure.(1)

(1) Steppacher SD, Tannast M, Ganz R, Siebenrock KA. Mean 20-year followup of Bernese periacetabular osteotomy. Clin Orthop Relat Res. 2008; 466:1633-1644.



Hip Dysplasia: Notice the upward slanted hip socket and femoral head undercoverage.



After periacetabular osteotomy. Notice the sockets are horizontal and fully cover the femoral head.



Meet our team of Physicians

For appointments, please call

(727) 898- BONE (2663) or (813) 879 BONE (2663)

For more information please visit www.chortho.com



Jeff Neustadt, M.D.

Board certified and fellowship trained in pediatric orthopaedic and scoliosis surgery.



Scott Beck, M.D.

Board certified and fellowship trained in pediatric orthopaedic surgery.



Greg Hahn, M.D.

Board certified and fellowship trained in pediatric orthopaedic and scoliosis surgery.



Drew Warnick, M.D.

Board certified and fellowship trained in pediatric orthopaedic surgery with an emphasis in sports medicine and hip preservation



Paul Benfanti, M.D.

Board certified and fellowship trained in pediatric orthopaedic and spinal deformity surgery.