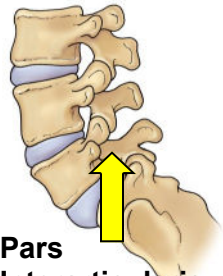


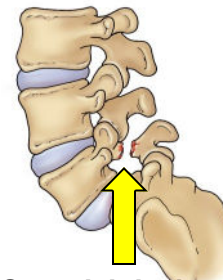
Understanding Spondylolysis & Spondylolisthesis

What is Spondylolysis and Spondylolisthesis?



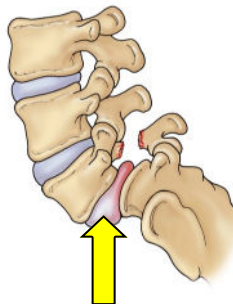
Pars Interarticularis

The pars interarticularis is a portion of the lumbar spine that joins the upper and lower joints together. The pars is normal in the majority of children.



Spondylolysis

Spondylolysis is a stress fracture in one of the vertebrae that make up the spinal column. It usually affects the fifth lumbar vertebra in the lower back or, much less commonly, the fourth lumbar vertebra.



Spondylolisthesis

Spondylolisthesis occurs if the stress fracture weakens the vertebrae so much that it is unable to maintain its proper position and shifts forward out of place.

X-rays may discount several of the potential diagnoses and direct the physician to propose the diagnosis of a pars interarticularis stress injury or fracture.

Causes

Genetics

- There may be a hereditary aspect to spondylolysis. An individual may be born with thin vertebral bone and therefore may be vulnerable to this condition. Significant periods of rapid growth may encourage slippage.

Overuse

- Some sports, such as gymnastics, weight lifting, and football, put a great deal of stress on the bones in the lower back. They also require that the athlete constantly hyperextend the spine. However, all athletes with spondylolysis are at risk of developing low back pain.

The adolescent with lumbar back pain may have multiple reasons other than overuse or "growing pains" for the discomfort. (Table 1)

Metabolic:	Juvenile osteoporosis
Inflammatory:	Ankylosing Spondylitis Sero-negative Arthritis
Neoplasm:	Osteoid osteoma
Congenital:	L5-S1 facet Hypoplasia
Developmental:	Lumbar Scheurmann's
Trauma:	Pars interarticularis Stress fracture

Diagnostic Imaging May Include:

- Plain x-ray
- 3 phase bone scan with SPECT imaging
- MRI
- CT Scan

Symptoms

- In many people where spondylolysis and spondylolisthesis are present, there are not any obvious signs or symptoms. No treatment is necessary in these cases.
- Pain usually spreads across the lower back and may feel like a muscle strain.
- Pain may occur only sporadically or may be continuous. Sporting activities may exacerbate the pain. Pain on hyperextension is a classic sign for a possible spondylolysis or spondylolisthesis.
- Spondylolisthesis can cause spasms that stiffen the back and tighten the hamstring muscles, resulting in changes to posture and gait. If the slippage is significant, it may begin to compress the nerves and narrow the spinal canal leading to leg pain and possible bowel or bladder problems.

Examination

- The clinical examination provides information about the location of the pain, muscle spasm, lumbar spine range of motion, hamstring muscle tightness, muscle strength in the legs, reflexes, and sensation in the legs and feet.
- The doctor measures standing lateral spine X-rays. This determines the amount of forward slippage.
- If spondylolysis is suspected, your orthopedist may order a bone scan to help further evaluate the stress fracture.
- If the vertebra is pressing on nerves, a CT scan or MRI may be needed before treatment begins to further assess the abnormality.

Treatment Options



Children's Orthopaedic
and Scoliosis Surgery Associates, LLP

Each child is different, and your physician will suggest the best treatment option for the child. These include:

Observation

Continually observing a small stress fracture to check for progression as the child or adolescent grows.

Bracing

Your orthopedist may recommend bracing to help stabilize the spine and allow the spondylolysis to heal. This light weight brace may be worn full time for up to 12 weeks. Physical therapy may follow bracing depending on each patient's personal needs.



Surgery

Surgery is performed in only the most severe cases. This may be needed if slippage progressively worsens or if back pain does not respond to non-surgical treatment and begins to interfere with activities of daily living. For spondylolisthesis, a spinal fusion is performed between the lumbar vertebra and the sacrum. This involves placing a system of screws and rods to stabilize the spine, and may involve a trans-laminar inter-body fusion as well. Spondylolysis surgery may be limited to actual repair of the fracture.

Jeffrey B. Neustadt, M.D.
Gregory V. Hahn, M.D.
Drew E. Warnick, M.D.
Paul L. Benfanti, M.D.
Lee G. Phillips, M.D.
Daniel C. Bland, M.D.
T. Cooper Wilson, M.D.



625 6th Avenue South, Suite 450
St. Petersburg, FL 33701
Phone: (727) 898-2663 - Fax: (727) 568-6836

3440 W. Dr. MLK Jr. Blvd, Suite 200
Tampa, FL 33607
Phone: (813) 879-2663 - Fax: (813) 872-0286

5881 Rand Blvd
Sarasota, FL 34238

4443 Rowan Road
New Port Richey, FL 34653

3850 Tampa Road
Palm Harbor, FL 34684

www.chortho.com

Spondylolysis & Spondylolisthesis

